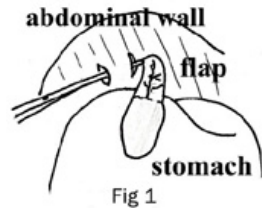


VARIOUS GASTROPEXY PROCEDURES

Type of Gastropexy	Pros	Cons
Belt Loop	Fast, simple, strong Decreased risk of stomach leakage Stomach fixed to Right abdominal wall	Requires more skill than incisional pexy
Circumcostal	Strong, decreased risk of stomach leakage Stomach fixed to Right abdominal wall	Risk of pneumothorax, risk of rib fracture. Requires more time to do, more difficult
Incisional	Fast, simple Stomach fixed to Right abdominal wall Decreased risk of stomach leakage	More variation in healing and resultant strength Relies on only a few sutures in place until adhesion forms
Ventral	Fast, Decreased risk of stomach leakage	Adhesions may impair future surgery if ever needed Difficult due to depth of the BH abdomen
Tube gastrostomy	Strong adhesions Allows for release of built up gas/fluid post GDV	Stomach has to be opened to insert tube risk of leakage Special post-op management, not as strong as other techniques, premature failure of tube, peritonitis, possible persistent fistula

References: Ventral Gastropexy: JAVMA Nov 1993
 (the following are all from Slatter, Textbook of Small Animal Surgery, Vol. 1 2nd Ed.)
 Belt Loop Gastropexy p. 587-588, Circumcostal Gastropexy: p. 586-587
 Incisional Gastropexy: p. 588-590, Tube Gastropexy: p. 586

Belt-Loop Gastropexy

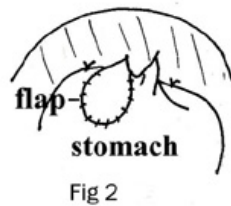


This technique is simple, rapid, and safe, and is my personal favorite on large breed dogs such as the Bloodhound. **Belt loop gastropexy has a much lower recurrence rate of torsion than tube gastrotomy as well as a much stronger adhesion than either tube gastrotomy or incisional gastropexy.** Since the stomach is not entered, there is not the risk of leakage of stomach contents or possible associated peritonitis. A 4 cm by 3 cm seromuscular flap is made in the pyloric antrum (stomach outlet), with a gastric vessel centered in the flap. Two small incisions, 3 cm apart, are made in the transverse muscle behind the last rib. The seromuscular flap of the stomach is passed through these incisions in the abdominal wall, and the flap is then re-sutured to the stomach (Fig 1 and 2). Stay sutures are also placed to hold the stomach to the abdominal wall. The flap incision in the stomach heals back to itself, and a strong adhesion forms between the stomach and the abdominal wall. The stay or tack sutures eventually break down, but the strength of the pexy is in the adhesions and the healed stomach flap. Anchoring the stomach to the right abdominal wall prevents the stomach from rotating on its axis.

Formatted: Highlight

Comment [maz1]: Needs a reference for this assertion.

Circumcostal Gastropexy



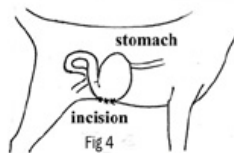
Circumcostal gastropexy has comparable strength to the belt loop gastropexy, and similarly does not have the risk of stomach leakage, as does the tube gastrotomy. Circumcostal gastropexy is more difficult to perform and the surgical procedure has potential risks of rib fracture or pneumothorax. The technique of forming the seromuscular flap in the pyloric antrum is the same as the belt loop gastropexy. The flap is passed around a rib instead of through a muscle tunnel. A 5 cm incision is made over

Comment [maz2]: Needs a reference for his assertion.

Formatted: Highlight

the last rib through the peritoneum and transverse muscle layer. The flap is passed through this incision, around the rib, and then sutured back to the stomach.

Incisional Gastropexy

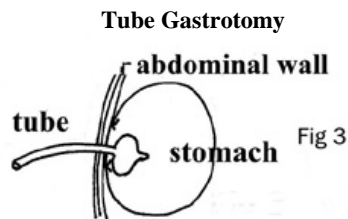


Incisional gastropexy is relatively simple and easy to perform. An incision is made into the seromuscular layer of the pyloric antrum, and a matching incision is made in the abdominal muscles. The edges of the gastric incision are sutured to the abdominal wall in a continuous pattern. As the incisions heal, adhesions form to hold the stomach to the abdominal wall

Ventral Incisional Gastropexy

This is a variation of the incisional gastropexy, except the stomach is incorporated in the mid abdominal incision as it is closed (Fig 4). This is a fast and simple procedure, but there are several possible complications. Due to the resultant position of the stomach and the adhesions, if a future abdominal surgery is necessary, the gastropexy will make it more difficult to enter the abdomen, and the pexy will have to be broken down. Also in a very deep-bodied breed, it is more difficult to correctly position the stomach

Tube Gastrotomy



Tube gastrotomy is relatively fast and easy to perform. It provides a means of decompression of

the stomach post-bloat, and forms adhesions that hold the stomach to the abdominal wall, thus preventing rotation. There are several potential complications from this type of procedure including: premature detachment of the tube, generalized peritonitis or cellulitis associated with leakage of gastric contents, persistent stoma or fistula . Post operative care is greater for this technique. Tube gastrotomy involves placement of a Foley catheter through an incision in the abdominal wall and then through an incision into the stomach lumen. Stay sutures are placed to hold the stomach to the abdominal wall (Fig 3). The tube is left in place for 7-10 days allowing adhesions to form between the stomach and abdominal wall. The tube is then pulled, and the stoma (or hole) gradually contracts and closes

